



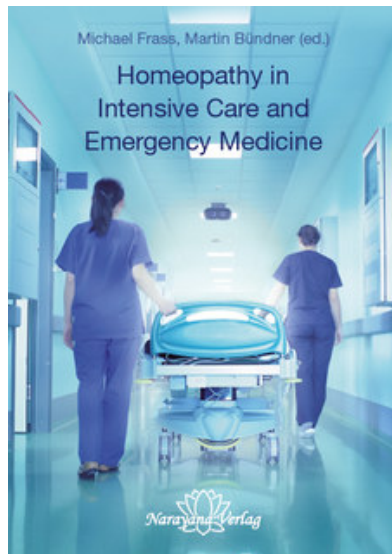
Frass / Bündner Homeopathy in Intensive Care and Emergency Medicine

Leseprobe

[Homeopathy in Intensive Care and Emergency Medicine](#)

von [Frass / Bündner](#)

Herausgeber: Narayana Verlag



<http://www.unimedica.de/b14188>

Sie finden bei [Unimedica](#) Bücher der innovativen Autoren [Brendan Brazier](#) und [Joel Fuhrmann](#) und [alles für gesunde Ernährung](#), [vegane Produkte](#) und [Superfoods](#).

Copyright:

Unimedica im Narayana Verlag GmbH, Blumenplatz 2, D-79400 Kandern

Tel. +49 7626 9749 700

Email info@unimedica.de

<http://www.unimedica.de>

Table of contents

I	Introduction	1	4.2.1	Plants	39
1	Homeopathy in intensive care and emergency medicine . . .	3	4.2.2	Fungi and lichens	39
1.1	Using homeopathy in a clinical setting	3	4.2.3	Minerals and metals	39
1.2	Principles of classical homeopathy.	5	4.2.4	Animal kingdom	39
2	Intensive medicine: development and current status	17	4.2.5	Products of disease, nosodes . . .	41
3	Aspects of adjuvant homeopathic treatment in intensive medicine	27	4.3	Quality criteria	42
3.1	General	27	4.4	Potentisation	43
3.2	Anamnesis	28	4.4.1	Source materials	43
3.3	Information	28	4.4.2	Potentisation: dilution and succussion	43
3.4	Administering remedies/choice of potency/repeat administration . .	28	4.4.3	Types of potency	45
3.5	Assessment/changing remedies/follow-up.	29	4.4.4	Triturations	48
3.6	Indications/contraindications . .	29	4.4.5	Labelling	49
3.7	Combining conventional and homeopathic medications and viewpoints.	30	4.4.6	Prescription	50
3.8	Continuing homeopathic treatment after periods in ICU.	31	4.4.7	Shelf-life of homeopathic remedies	51
3.9	End-of-life care	31	4.4.8	Drug legislation	51
3.10	Effects on the climate in ICU wards	32	4.4.9	Taking potentised remedies	53
3.11	Suggestion and placebo effects . .	32	4.4.10	Methods of administration	53
3.12	Summary and studies.	32	4.5	Homeopathic Pharmacopoeia . . .	53
4	Remedy production and quality	37	4.6	ICU remedy kit	55
4.1	Pharmaceutical aspects of homeopathy in intensive care medicine	37	II	Intensive care medicine	85
4.2	Source materials used in potentised homeopathic remedies.	38	1	Infectious diseases	87
			1.1	Sepsis	87
			1.2	Serious local infections	111
			1.2.1	Ludwig's angina (Quinsy)	112
			1.2.2	Hip joint abscess	116
			1.2.3	Cricoid perichondritis	118
			2	Disorders of Haemostasis . . .	121
			2.1	Thrombotic thrombocytopenic purpura (TTP)	122
			2.2	Bleeding after therapeutic puncture wound	126
			2.3	Pulmonary embolism	128
			3	Heart, circulation and blood vessels	133
			3.1	Angina pectoris	134
			3.2	Myocardial infarction.	138
			3.3	Aortic dissection	142

3.4	Cardiomyopathy, heart transplant	146	10	Cardiovascular emergencies	253
3.4.1	Cardiomyopathy	146	10.1	Cardiac arrhythmias	253
3.4.2	Heart transplant	152	10.2	Hypertensive crisis	259
3.5	Pulmonary oedema	154	10.3	Pulmonary embolism	264
4	Lungs	167	10.4	Acute venous occlusion	271
4.1	Lung diseases	167	10.5	Angina pectoris and myocardial infarction	276
4.1.1	Acute Respiratory Distress Syndrome (ARDS)	168	10.6	Cardiac arrest (resuscitation)	285
4.1.2	Pneumonia	175	11	Lungs	293
4.2	Withdrawal from respirator and extubation	179	11.1	Asthma bronchiale	293
4.2.1	Withdrawal from respiration devices (weaning)	179	11.2	Pulmonary oedema	304
4.2.2	Extubation	185	11.3	Hyperventilation syndrome (tetany)	309
5	Kidneys	189	12	Gastroenterological emergencies	315
5.1	Homeopathy in cases of kidney disease	189	12.1	Acute abdomen	315
5.2	Acute renal failure (ARF)	190	12.2	Homeopathic treatment	318
6	Gastrointestinal tract	195	13	Intoxication	347
6.1	Homeopathy for diseases of the gastrointestinal tract	195	13.1	Drugs	347
6.2	Acute abdomen	196	13.2	Intoxication from medication	352
7	Perioperative care	199	13.3	Poisoning with industrial and household substances	361
7.1	Intraoperative blood loss	200	14	Neurological emergencies	381
7.2	Postoperative transitory psychotic syndrome	204	14.1	Apoplexy and intracranial bleeding	381
8	Toxicology	213	14.2	Epilepsy	401
8.1	Homeopathy in case of poisoning	213	14.3	Meningitis and encephalitis	408
8.2	Death cap mushroom poisoning	214	14.4	Disc prolapse	413
III	Emergency medicine	219	15	Psychiatric emergencies	417
9	Traumatology	221	15.1	Delirium	418
9.1	Trauma to the extremities	229	15.2	Agitation	420
9.2	Spinal trauma	237	15.3	Acute psychosis	424
9.3	Thoracic trauma	242	16	Gynaecology and obstetrics	431
9.4	Craniocerebral trauma (CCT)	244	16.1	Genital bleeding outside pregnancy	431
9.5	Abdominal trauma	249	16.2	Emergencies during pregnancy	436

16.3	Birth and birth complications . . .	445
16.3.1	Normal birth	445
16.3.2	Birth complications.	445
17	Urological emergencies.	457
17.1	Acute urinary retention	457
17.2	Renal and ureteral colic	461
17.3	Urosepsis (UTI)	465
17.4	Injuries to the urogenital tract . .	471
18	Thermal emergencies	477
18.1	Hypothermia and frostbite	477
18.2	Burns and scalds.	484
18.3	Heat damage	490
IV	Materia medica	497
19	Materia medica	499
19.1	Introduction	499
19.2	Materia medica.	500
	Index of remedies	525
	Index	529

Case 5.2-1: Acute kidney failure

Michael Frass

Anamnesis

A 68-year-old male patient develops acute kidney failure after suffering severe respiratory insufficiency. The patient's case history includes a tonsillectomy in his childhood and a cholecystectomy performed at the age of 42 due to cholecystolithiasis. The patient also has recurring bouts of Crohn's disease, which first manifested at the age of 47. The patient was operated on for fistulae and underwent several partial resections. However, at the time of the acute event he had no symptoms and was not taking any medication. The patient was diagnosed with diabetes mellitus type II three years previously. This is being treated with metformin (e.g. Glucophage®).

Acute event

The patient was admitted to hospital with pneumonia. In the general chest x-ray, a shadow was observed at the apex of the right lung. On the general ward, the patient suddenly developed dyspnoea and was transferred to ICU with acute respiratory failure (day 0). An endotracheal tube was inserted, he was sedated and controlled artificial respiration was given (BIPAP, FiO₂ of 75%, pressures: 30 and 10 cmH₂O). He also showed signs of sepsis with a focus suspected in the lung. His temperature was 39.2°C, he had tachycardia (heart rate 95/min.), his leucocyte count was 15.6 g/l. One striking symptom was profuse sweating of the head at night.

Diagnoses

Acute kidney failure, Crohn's disease, pneumonia.

Conventional treatment

It was found that the patient had anaemia, elevated beta 2 microglobulin and elevated C-reactive protein (CRP); a computed tomography of the abdomen was consequently performed, raising the suspicion that he had an abdominal tumour. Histological examination of the biopsy revealed that he had abdominal non-Hodgkin lymphoma (NHL).

Homeopathic treatment**Repertorisation I****COMPLETE REPERTORY**

Chest – inflammation – lungs – right – upper

Generalities – fistulas

Rectum – fistulas

Head – sweating – night

Generalities – carcinoma

Differentiation between remedies

Silicea could be considered in terms of differential diagnosis; however, the location of the shadow does not indicate this remedy. *Calcarea carbonica* is the main remedy indicated on repertorisation; this also includes nocturnal sweating of the head as a symptom.

Prescription

On day 3, the patient is given 1 dose of 5 globules *Calcarea carbonica* 200C.

Progress

The shadow in the upper lobe of the right lung subsides rapidly over the next four days; the sedatives are stopped. On day 5, the respiratory pressure is adjusted to pressure support with a FiO₂ of 40%. The signs of sepsis subside at the same time. Surprisingly, acute renal failure (ARF) sets in on day 6. The plasma concentration of creatinine and BUN increase dramatically over the next few days. A cloudy sediment is observed in the patient's urine. Continuous venovenous haemofiltration seems inevitable in view of his declining kidney function. As the homeopath was temporarily absent, the patient was not able to begin homeopathic treatment until day 16. The patient reported pain in the kidney area radiating into the thighs.

Repertorisation II**COMPLETE REPERTORY**

Kidneys – pain – extending to – thigh

Urine – scanty

Urine – sediment – cloudy

Differentiation between remedies

Drainage remedies such as *Solidago* and *Lespedeza sieboldii* could be considered. However, the radiating pain indicates *Berberis*.

Prescription

Berberis 12C three times a day on day 16.

Progress

On day 17, the patient's plasma creatinine and BUN counts decrease and his urine output increases. He does not require kidney replacement therapy.

On day 25, he is transferred to a general ward. There are no further complications; the patient is discharged for home nursing on day 40.

Evaluation

This case shows how homeopathy can be used to treat organ failure, firstly of the lungs and secondly of the kidneys. Fortunately, the patient had one important symptom, i.e. the pain radiating into the upper thighs. This case clearly shows the importance of taking a thorough case history for choosing the correct remedy.

Critical commentary

It must be observed that the patient's recovery may also have taken the same course if left to nature. Once the creatinine plateau had been reached, the kidney failure may have resolved spontaneously, meaning that the influence of the homeopathic treatment must be called into question.

Bibliography

Better OS, Stein JH: Early management of shock and prophylaxis of acute renal failure in traumatic rhabdomyolysis. *N Engl J Med* 1990 (322): 825 – 829.

Braun R, Preuss R: *Klinikleitfaden Intensivmedizin [Clinical Guidelines Intensive Medicine]*. 5th edition, Urban & Fischer, Munich 2002.

Broadbudd VC, Berthiaume Y, Biondj JW et al.: Hemodynamic management of the adult respiratory distress syndrome. *J Intensive Care Med* 1987 (2): 190 – 213.

Burchardi H, Larsen R, Schuster HP, Suter PM: *Die Intensivmedizin [Intensive Medicine]*. 9th edition, Springer, Berlin/Heidelberg 2004.

Chertow GM, Levy EM, Hammermeister KE, Grover F, Daley J: Independent association between acute renal failure and mortality following cardiac surgery. *Am J Med* 1998(104): 343 – 348.

Cockcroft DW, Gault MH: Prediction of creatinine clearance from serum creatinine. *Nephron* 1976 (16): 13.

Denton MD, Chertow GM, Brady HR: "Renal dose" dopamine for the treatment of acute renal failure: scientific rationale, experimental studies and clinical trials. *Kidney Int* 1996 (49): 4 – 14.

Eckardt KU: Renal failure in liver disease. *Int Care Med* 1999 (25): 5 – 14.

Frass M, Popovic R, Hartter E, Auinger C, Woloszczuk W, Leithner C: Atrial natriuretic peptide decrease during spontaneous breathing with continuous positive airway pressure in volume-expanded healthy volunteers. *Crit Care Med* 1988 (16): 831 – 835.

Friedrich JO, Adhikari N, Herridge MS, Beyene J: Meta-analysis: low-dose dopamine increases urine output but does not prevent renal dysfunction or death. *Ann Intern Med* 2005 (142): 510 – 524.

Holmes RP, Ambrosius WT, Assimos DG: Dietary oxalate loads and renal oxalate handling. *J Urol* 2005 (174) 943 – 947.

Latasch L, Knipfer E (ed.): *Anästhesie Intensivmedizin Intensivpflege [Anaesthesia Intensive Medicine Intensive Care]*. 2nd edition, Elsevier/Urban & Fischer, Munich 2004.

Leithner C, Frass M, Pacher R, Hartter E, Pesl H, Woloszczuk W: Mechanical ventilation with positive end-expiratory pressure (PEEP)

decreases release of alpha-atrial natriuretic peptide. *Crit Care Med* 1987 (15): 484 – 488.

Lieberthal W: Biology of acute renal failure: Therapeutic implications. *Kidney Int* 1997 (52): 1102 – 1115.

Marino PL, Taeger K: *Das ICU-Buch. Praktische Intensivmedizin [The ICU book. Practical intensive medicine]*. 3rd edition, Urban & Fischer, Munich 2002.

Mezger J: *Gesichtete Homöopathische Arzneimittellehre [Proven homeopathic materia medica]*. Haug, Heidelberg 1997

Pacher R, Frass M, Hartter E, Woloszczuk W, Leithner C: Continuous pump-driven hemofiltration associated with a decline in alpha-natriuretic peptide. *Crit Care Med* 1986 (14): 1010 – 1014.

Ronco C: Extracorporeal therapies in acute rhabdomyolysis and myoglobin clearance. *Crit Care* 2005 (2): 141 – 142.

Scolari F, Bracchi M, Valzori B, Movilli E et al.: Cholesterol atheromatous embolism: An increasingly recognized cause of acute renal failure. *Nephrol Dial Transpl* 1996 (11): 1607 – 1612.

Shilliday I, Quinn KJ, Allison MEM: Diuretics in acute renal failure. *Renal Failure* 1994 (16): 3 – 17.

Swartz RD, Bustami RT, Daley JM, Gillespie BW, Port FK: Estimating the impact of renal replacement therapy choice on outcome in severe acute renal failure. *Clin Nephrol* 2005 (63): 335 – 345.

Thadhani R, Pascual M, Bonventre JV: Acute renal failure. *N Engl J Med* 1996 (334): 1448 – 1460.

Tucci M, Calvani N, Richards HB, Quatraro C, Silvestris F: The interplay of chemokines and dendritic cells in the pathogenesis of lupus nephritis. *Ann NY Acad Sci* 2005 (1051): 421 – 432.

Uchino S, Kellum JA, Bellomo R, Doig GS et al.: Beginning and Ending Supportive Therapy for the Kidney (BEST Kidney) Investigators. Acute renal failure in critically ill patients: a multinational, multicenter study. *JAMA* 2005(294): 813 – 818.

Wetmore JB, Hung AM, Lovett DH, Sen S et al.: Interleukin-1 gene cluster polymorphisms predict risk of ESRD. *Kidney Int* 2005 (681): 278 – 284.

Zandvoort R v (ed.): *Complete Repertory*. Kent Homeopathic Associates Inc., San Rafael 2000

Progress

All symptoms begin to improve, slowly at first then more rapidly towards evening. On day 4, the patient's condition is continuing to improve but she notices a kind of fog in front of the eye, as if she were looking through a veil. Initially, no further action is taken and further developments awaited. On day 5, the symptoms have again worsened to some degree; the patient is then given *Pulsatilla* 200C. Afterwards, the symptoms subside markedly within about two hours and a whitish mass is discharged from the eye; in retrospect, this is likely to have been the remains of the dye. After this mass is secreted, all the symptoms described, which had persisted up to that point, disappear within another two hours.

Evaluation

Homeopathic remedies are also effective in treating external causes, e.g. when the organism is retaining

foreign bodies; in such cases, they may eliminate them from the body, for example via a purulent discharge.

Critical commentary

It should naturally be considered whether the patient should have been sent to an eye specialist. An ophthalmological consultation would by all means have been advisable, but was rejected by the patient as the symptoms began to improve with homeopathic treatment after the first dose of *Pulsatilla* was given.

Only considering the current and most recently occurring symptoms and overlooking the past ones might perhaps also lead to a successful choice of remedy, but is unnecessarily hazardous and does not do justice to the case.

Case 13.3-3: Anaphylactic shock

Martin Bündner

Anamnesis

The eight-month-old girl suffers from a milk allergy and severe neurodermatitis. The milk allergy manifests as massive vomiting after she eats a little milk pudding. Subsequently, hives form on her face and on the areas which came into contact with the vomit; the child scratches herself in these places. After licking an ice cream, her right eyelid swells and hives form around her mouth and on her cheeks. After eating milk chocolate, hives form on the areas of skin which were smeared with chocolate. They also form on the skin under the chocolate stains on her T-shirt. The parents avoid giving her foods which contain milk. As yet, it is unknown whether she is allergic to egg white, but the parents are currently trying to avoid foods containing egg white equally strictly for fear of another allergy.

One evening, the baby is given a small piece of pasta with home-produced fresh egg. After the meal, the girl suddenly begins to scream uninterruptedly at quite a low pitch, which is completely untypical.

Her cheeks seem to be itching, as she keeps scratching them. She then convulsively stretches her whole body backwards. After a few minutes, she relaxes and appears to return to normal. Half an hour later, she falls asleep at a time which is unusual for her, and wakes up half an hour later. She now appears to be back to her old self. The evening proceeds absolutely normally; she seems to have come through it safely. The homeopathic doctor treating her advises the mother just to breastfeed her for the time being without giving any additional food. At the mother's wish, the child remains at home and is not taken to a clinic for monitoring, contrary to the doctor's advice. The parents are then told to contact the doctor immediately if the slightest sign of another reaction appears.

There are no unusual occurrences in the night. However, next morning, the girl is found to be sweating profusely on her back and the back of her head, although she is no more warmly dressed than on the previous nights and there has been no change in room temperature. Her nappy is found to contain greenish-brown stool, which smells fermented and

extremely sour. The consistency is soft and it contains food remnants, presumably from the pudding. Suddenly, the mother sees large, red, hot hives appear at the lower edge of the nappy; the skin is raised. She is using the same brand of nappy as usual. The homeopathic doctor is notified immediately and he sets off right away to make a house call. Before he arrives, the situation worsens dramatically within a few minutes: the hives spread rapidly upwards over the abdomen, armpits, throat, neck and face. The baby cries shrilly and scratches herself all over, causing the hives to increase in size. Suddenly her face turns ashen, then as white as chalk; even her lips are affected. The girl's eyes roll inwards and she loses consciousness. She collapses, stops crying, no longer responds when spoken to. She appears lifeless; only her shallow breathing shows that she is still alive. The mother panics and is about to call emergency services when the homeopathic doctor arrives. As the baby is still alive, the situation is evaluated quickly. It would take more than ten minutes for emergency services to arrive. However, with these clear symptoms, a homeopathic remedy is quickly found. The emergency services are not ideally equipped to deal with this special case of anaphylactic shock in a baby; transport to the nearest clinic would take about half an hour even if special rights were utilised. There are no corticoids or adrenaline available, as a result of which the doctor decides to administer emergency homeopathic treatment taking all circumstances into consideration.

Diagnosis

Anaphylactic shock. Neurological symptoms. Neurodermatitis. Multiple allergies. Atopic diathesis.

Homeopathic treatment

This case is characterised by the following symptoms: the general symptoms are the comatose sleep, the sudden manifestation (which can be repertorised in parallel using the pain rubric), the specific location of the unusual sweating, the hives moving upwards and the opisthotonos of the previous evening, which is part of the symptom complex and must therefore be incorporated into the

case. The skin manifestation is characterised more specifically by the heat over the rash.

The rolled-in eyes are merely an unusual local symptom. However, this cerebral involvement is unusual for an allergic reaction and therefore very important for finding the right remedy, which is why this symptom along with the opisthotonos and the comatose sleep is given precedence over the other general symptoms during the repertorisation process.

Repertorisation

KENT'S REPERTORY

Perspiration – single parts – lain on

Back – opisthotonos

Sleep – comatose

Eye – turned – inwards

Generalities – pain – appears suddenly

Skin – eruption – urticaria

Skin – heat – without fever

Differentiation between remedies

Belladonna is the only remedy listed in all these rubrics, where it is invariably weighted doubly or triply. The only exception is the heat rubric, in which except for two doubly weighted remedies, the remaining 24 remedies (including *Belladonna*) are weighted singly. *Aconitum* and *Pulsatilla* might also be possible.

However, *Aconitum* does not have the typical rash and *Pulsatilla* is not a perfect match because it does not cover the neurological symptoms sufficiently.

The upward movement of the symptoms is typical of *Belladonna*. This is not mentioned in the repertory but can be found in the materia medica, possibly in connection with another symptom, when working up the case.

Prescription

2 doses of 1 drop *Belladonna* Q6.

Progress

Just a few seconds after administering *Belladonna*, some signs of life reappear; the eyes are no longer rolled inwards but have returned to normal. This good sign is hopeful and reassuring, and is

confirmed by the baby's further progress. The *Belladonna* Q6 is shaken and she is given another drop. Within another 20 to 30 minutes, the rash progressively subsides from top to bottom in accordance with Hering's Law and the girl's reactions return to normal. The last hives disappear during the day. No more doses are given on this day, as the remedy is taking effect slowly but surely and should not be disrupted by another dose. Afterwards, the girl is given long-term treatment with *Belladonna* (1 drop *Belladonna* Q6 daily after shaking the bottle), which continues to have a positive effect.

Evaluation

The child would presumably have died if an attempt had been made to initiate conventional treatment, as the time available was so short.

Critical commentary

In this extremely dangerous situation, in which there is hardly any time for the customary careful selection of the homeopathic remedy, the reparation process must begin with an elimination rubric which should be not too big, nor so small that critical remedies may be omitted.

The materia medica comparison (Hahnemann 1830) performed later confirms the outstanding similarity of the remedy to this case, which ultimately facilitated successful treatment:

Belladonna: "*Belladonna*, in the small dose just described, is, if the case is homeopathically adapted, capable of curing the most acute diseases (in which

it acts with a rapidity proportionate to the nature of the disorder) [...]. Paleness of face [...]. Sudden paleness of face for a considerable time [...]. Great dullness of head and sight, [...] with very small, unequal, dark red spots, especially on the forehead, swollen face [...]. Red swollen face [...]. Red swollen face with staring eyes [...]. Swollen face [...]. The eyes [...] roll about in the head [...]. The eyeballs rove about in a circle spasmodically [...]. The eyes are distorted [...]. Spasms of the eyes [...]. The eyes are distorted, with redness and swelling of the face [...]. Curdled [...] stool [...]. Motions of a very sour smell [...]. Green stools [...]. The pain mounts gradually from the ankles to the hips [...]. Head and trunk drawn quite back to the left side, so that he could not walk [...]. Soporose state [...]. Very deep slumber [...]. Deep sleep [...]. Very deep sopor, with [...] pale cold face, cold hands and hard, small, rapid pulse [...]. Heat of the whole body, with violet redness of all the skin [...]. Redness of the whole body [...]. The whole body is swollen, burning hot, and red [...]. Redness and swelling of the affected part [...]. Chest and abdomen are covered with small, red, somewhat elevated, painless spots, that sometimes disappear and reappear, with general redness of the skin [...]. Blood-red spots all over the body, especially on the face, neck, and chest [...]. Night sweat [...]. Night sweat during sleep [...]. Sweat, that rose from the feet up into the face [...].

Case 13.3-4: Food poisoning

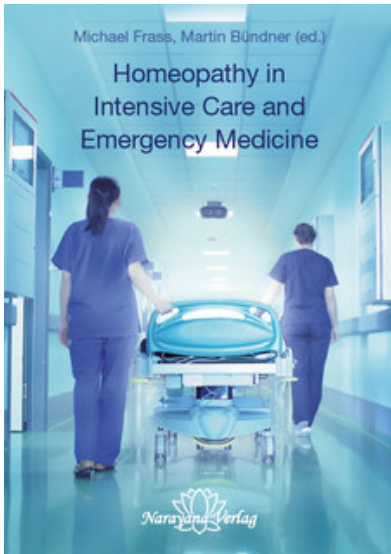
Martin Bündner

Anamnesis

The 46-year-old patient comes to the clinic in the evening; she is vomiting, has a feeling of pressure on the chest and her general condition is deteriorating rapidly. The symptoms appeared in the morning and have persisted ever since. As the symptoms cannot be clearly identified, she is admitted as an in-patient to rule out a heart condition. She had no thoracic pain at the time of admission; today is the

first time she has ever felt the pressure on her chest. The patient requests homeopathic treatment. The history reveals the following symptoms:

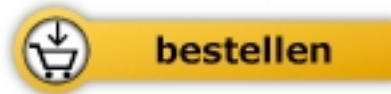- In the morning on the day of admission, she ate a two-day-old lemon which had been cut open and not carefully stored. Afterwards, she became nauseous and her general condition deteriorated significantly
- The nausea is located in the stomach and improves when she drinks
- Eating triggers nausea
- The patient has an appetite but is not hungry



Frass / Bündner

[Homeopathy in Intensive Care and
Emergency Medicine](#)

568 Seiten, geb.
erschienen 2015



Mehr Bücher zu gesund leben und gesunder Ernährung www.unimedica.de